

**Simultaneous surgical interventions in spinal neurosurgery: a systematic review**V.A. Byvaltsev<sup>1,2,3,4</sup>, A.A. Kalinin<sup>1,2</sup>, S.O. Ryabykh<sup>5</sup>, A.V. Burtsev<sup>5</sup>, V.V. Shepelev<sup>1</sup>, S.V. Ochkal<sup>1</sup>, R.A. Polkin<sup>1</sup>, M.Yu. Biryuchkov<sup>6</sup><sup>1</sup>Irkutsk State Medical University, Irkutsk, Russian Federation<sup>2</sup>Railway Clinical Hospital on Irkutsk-Passazhirskiy station, Irkutsk, Russian Federation<sup>3</sup>Irkutsk State Medical Academy of Postgraduate Education, Irkutsk, Russian Federation<sup>4</sup>Irkutsk Scientific Center of Surgery and Traumatology, Irkutsk, Russian Federation<sup>5</sup>Ilizarov National Medical Research Centre for Traumatology and Orthopedics, Kurgan, Russian Federation<sup>6</sup>West Kazakhstan Marat Ospanov Medical University, Aktobe, Kazakhstan

**Purpose** To conduct a systematic review of literature on the results of simultaneous surgical interventions (SSI) in spinal surgery to determine their value in the treatment of degenerative diseases, traumatic injuries, destructive changes due to tuberculous spondylitis, correction of congenital anomalies and tumor lesions. **Material and methods** A systematic search of literature in English and Russian published between January 1960 and December 2018 was conducted using the Medline, EMBASE, Cochrane Library and eLibrary databases. **Results** The systematic review included 20 studies on the use of simultaneous technology in the surgical treatment of degenerative diseases and injuries of the spine, tuberculous spondylitis, as well as rare combined pathologies. It has been established that SSIs used in combination with high-tech tools and minimally invasive surgical techniques are able to eliminate several diseases simultaneously, to preserve low invasiveness of the approach, to activate patients early and to reduce the number of complications. **Conclusion** There is a need to develop specialized criteria and an objective classification of SSI, as well as to study the effectiveness of various options for such interventions based on the parameters of the duration of surgery, volume of blood loss, duration of intraoperative exposure to radiation, duration of inpatient treatment and economic costs.

**Keywords:** degenerative and inflammatory diseases of the spine, traumatic spinal injuries, spine surgery, minimally invasive technologies, simultaneous surgical interventions

## INTRODUCTION

Additional requirements are imposed on surgical interventions at the current stage of spinal surgery such as decrease in the intervention time and blood loss, enhancement of economic efficiency in comparison with traditional methods of treatment [1, 2]. Various systems of retractors, specific to a certain anatomical corridor, various methods of low-impact decompression and stabilization, navigation systems and robotics have been used for this purpose [3, 4].

Despite a significant arsenal of high-tech instrumentation and equipment, there is still a need to improve the results of spinal surgical interventions, since the patient's relatively non-physiological position on the operating table, prolonged administration of anesthetic drugs, and exposure to radiation during neurosurgical stages are the risk factors of adverse

clinical outcomes in the peri-operative period [5, 6].

The technology of simultaneous surgical interventions is one of the ways to improve the outcome of operations on the spine. Our systematic review analyses the results of using SSI in spinal surgery, and also shows the options for using this technique in the treatment of degenerative diseases and injuries of the spine, tuberculous spondylitis and a rare combined pathology.

The **aim of the study** was to carry out a systematic review of the literature on the results of applying the technology of simultaneous surgical interventions in spinal surgery to determine its value in the treatment of degenerative diseases, traumatic injuries, destructive changes due to tuberculous spondylitis, correction of congenital anomalies and tumor lesions.

## MATERIAL AND METHODS

**Search strategy and literature selection**

Medline, EMBASE, Cochrane Library and eLibrary databases were searched for articles, published from January 1960 to December 2018,

describing the application of the SSI technology in spinal surgery. Data were obtained by two authors and independently reviewed by a third author. If there was a disagreement regarding the inclusion of studies

in the systematic review, the decision was taken collectively with the participation of all authors. The study was carried out in accordance with international recommendations for writing systematic reviews and meta-analyses PRISMA [7].

At the first stage, a search for literary sources was conducted with the keywords “minimally invasive spine surgery”, “simultaneous spine surgery”, “combined spine surgery”, “degenerative disk disease”, “inflammatory spine disease”, “traumatic spine injures” in the English-language and Russian-language databases. At the second stage, abstracts of articles were examined and publications that did not meet the research criteria were excluded. At the third stage, we reviewed the full texts of the selected articles for compliance with the inclusion criteria and a list of references for relevant studies (Fig. 1).

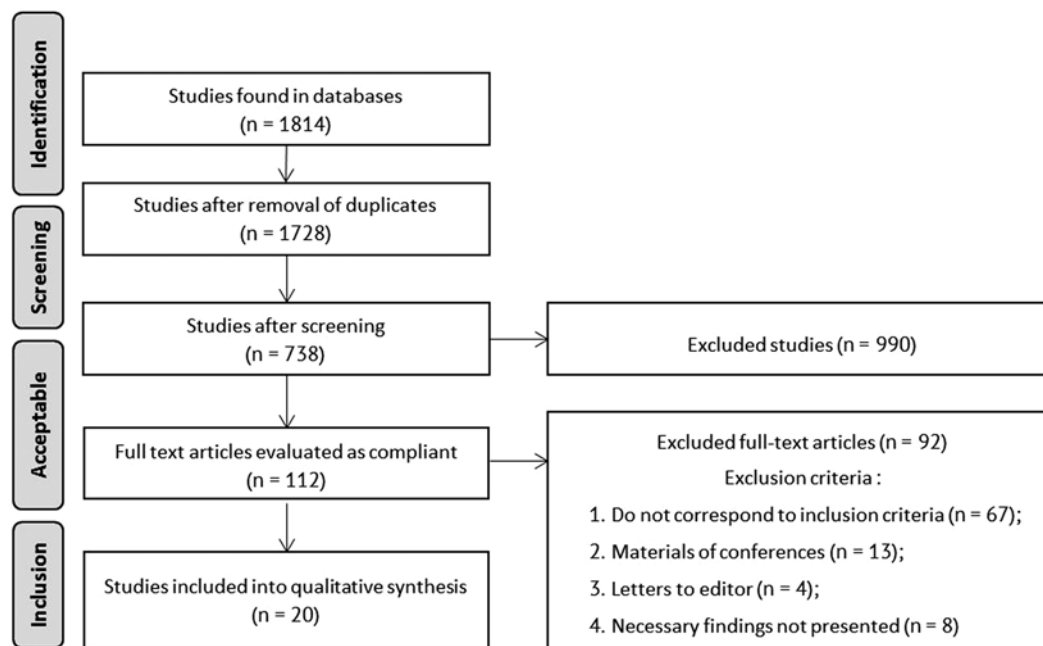


Fig. 1 Search strategy and selection of literary sources for the systematic study

## RESULTS

### Search of literature sources

According to the compliance criteria, this systematic review included 20 studies that used SSI in spinal surgery [9–10, 13–16, 20–21, 25–27, 32, 37–39, 42–46]. Of the 20 sources, six were cohort studies and case-control studies and were rated for the risk of systematic errors with the Newcastle-Ottawa scale. The general characteristics of the studies included in this systematic review are presented in Table 1. The remaining studies were systematic reviews or case reports.

### Compliance criteria

In order to analyze the use of the SSI technology in performing spinal neurosurgical interventions, the following criteria for the correspondence of literary sources were determined:

- 1) Studies included: retrospective and prospective cohort studies, case-control studies, systematic reviews, clinical cases studying the effectiveness of the SSI technology in spinal surgery;
- 2) Types of surgical interventions: surgical interventions on the cervical / thoracic / lumbar spine for treating various neurosurgical nosology;
- 3) Study design: all types of studies describing the use of the SSI on the spine were included.

### Assessment of bias and bias risk

Nonrandomized retrospective and prospective cohort studies and case-control studies were evaluated for the risk of systematic errors using the Newcastle-Ottawa scale [8].

### Simultaneous technologies in management of degenerative diseases of the spine

Degenerative diseases of the spine are one of the leading pathologies in spinal surgery. Each year, about 8 % of the working population develop disability to work due to vertebrogenic pain. Out of the total number of these cases, 40 % of individuals experience pain localized in the lumbar spine [9]. One of the degenerative pathologies of the spine, in which the use of SSI is rational, is tandem spinal stenosis. The incidence of simultaneous multiregional spinal canal stenosis in the population is from 7.6 to 60 % [10].

Table 1

## General characteristics of the studies included in this systematic review

Authors	Number of patients	Mean age (years)	Study design	Evidence level	Newcastle-Ottawa score	Spine department	Approach	Follow-up time (months)
Straus et al., 2002 [9]	-	-	Literature review	5	-	-	-	-
Overley et al., 2017 [10]	599	-	Systemic review	1	-	Cervical, thoracic	Posterior	-
Doniel et al., 2015 [13]	10/10	54.5/57.8	Prospective, case-control	3	5	Lumbosacral	Lateral + posterior	-
Jain et al., 2010 [14]	48	29,1	Prospective, cohort	3	4	Thoracic, lumbar	-	-
Kiyoshi et al., 2015 [15]	4	67.2	Case series	3	-	Cervical	Anterior + posterior	16.5
Cheung et al., 2016 [16]	-	-	Literature review	5	-	Cervical	Anterior + posterior	-
Shinbo et al., 2014 [20]	2	69	Case report	3	-	Cervical	Anterior + posterior	18
Koller et al., 2006 [21]	1	34	Case report	3	-	Cervical	Anterior	11
Xia et al., 1998 [25]	89	36.8	Retrospective, cohort	3	2	Thoracic	Anterior + posterior	48
Xia et al., 2009 [26]	34	34.2	Retrospective, cohort	3	5	Lumbosacral	Anterior + posterior	13
Mochino et al., 2011 [27]	100	36	Prospective, cohort	3	6	Thoracic, lumbar	Anterior + posterior	30
Mukhtar et al., 2003 [32]	22	-	Prospective, cohort	3	4	Thoracic, lumbar	Anterior + posterior	18
Manoj et al., 2018 [37]	30	9.8	Prospective, case series	3	-	Thoracic, lumbar	Posterior	49
Shahcheraghi et al., 2010 [38]	7/9	11.8/18.5	Case series	3	-	Thoracic	Anterior + posterior	80
Stoker et al., 2012 [39]	8	54	Case series	3	-	Cervical, thoracic	Posterior	16
Aydogan et al., 2007 [42]	8	68	Retrospective, case series	3	-	Cervical, lumbar	Anterior + posterior	34.6
Epstein et al., 1984 [43]	24	64	Case series	3	-	Cervical, lumbar	Posterior	-
Hsieh et al., 1998 [44]	12	-	Case series	3	-	Cervical, lumbar	Anterior + posterior	32
Kikuike et al., 2009 [45]	17	70.9	Case series	3	-	Cervical, lumbar	Posterior	36
Eskander et al., 2011 [46]	43	68	Case series	3	-	Cervical, lumbar	Posterior	84

In cases of symptomatic combined stenosis of the spinal canal, the operation is performed by stages or simultaneously [11]. Thus, first decompression may be carried out in the area of the most severe neurological deficit. Overley et al. showed that when two teams work simultaneously in the cervical and lumbar regions, the volume of blood loss and the duration of surgical intervention decrease in comparison with the sequential work of one surgical team, first at one and then at another level of the spine during one anesthetic procedure [10]. Another option for the treatment of tandem spinal stenosis is performance of separate surgical interventions in each affected segment of the spine. It was found that in some cases, surgical intervention at the cervical level, in the absence of severe symptoms in the lumbar spine, may result in complete disappearance of symptoms in the lower extremities [11]. Moreover, the use of staged treatment is recommended in patients over 60 years of age, which is associated with prolonged anesthesia and a large amount of blood loss in the cervical and lumbar SSIs [12]. The technique of surgical interventions varies depending on the severity of the pathological process and the level of damage, but the main phases of surgical treatment are approach, decompression and stabilization [13].

Also, SSI variants in the treatment of degenerative diseases of the spine are cases with several fixation systems from different approaches to ensure sufficient stability of the vertebral segments. In the lumbar spine, a combination of posterior and lateral types of fixation is often used [14]. These surgical interventions are performed in the patient's position on his/her side, which allows not changing the patient's position on the operating table. Manipulations are sequential within one anesthesia session. In the cervical spine, the most common method is simultaneous implantation of ventral and dorsal stabilizing structures [9]. Such surgical interventions are commonly used in the treatment of patients with deformities in the areas with an increased axial load (transitional zones of the spine) [15]. The need for this type of surgical interventions is due to the need for effective fixation of the affected zone. To implement this technology, after ventral decompression of neural structures and interbody stabilization with a cage, the patient is turned over for dorsal screw fixation [16].

#### ***Simultaneous interventions in the treatment of traumatic injuries of the spine***

More than 8,000 persons become disabled annually in the Russian Federation due to spinal

cord and spinal cord injuries [17]. Closed injuries of the second cervical vertebra are considered to be one of the most common in the cervical spine and make up more than 20 % [18, 19]. Moreover, multiple fractures of the second cervical vertebra are much less common and are recorded in 1 % of all cervical injuries [20]. Management of such patients remains controversial for spinal surgeons. Recently, combined surgical treatment methods have been widely used applying simultaneous technologies, which achieve high primary stability, early activation of the patient and provide good clinical and radiological results [21]. So, Shinbo et al. report two patients with three-component C2 vertebral fractures, consisting of a type II odontoid fracture and Levine-Edwards type 2–3 fractures, operated simultaneously with anterior fixation of the dentoid process with a screw and bilateral transpedicular posterior screw fixation. Patients showed sufficient stability of damaged bone structures, which allowed for early mobilization and preservation of the range of motion of the cervical spine at levels C1 – C2 and C2 – C3 [20].

Thoracolumbar fractures are a frequent type of spinal injury, which has become the most common due to industrialization [22, 23]. In addition to compression, such damage occurs due to twisting or tangential deformities, accompanied by subluxation and dislocation of the vertebrae [24]. Although the choice of tactics for surgical treatment of thoracolumbar fractures remains controversial, in most of these cases, either ventral or dorsal surgical approaches are used. With significant post-traumatic deformities and displacements of bone fragments, the combination of anterior and posterior approaches is justified [25]. In these cases, sufficient decompression and effective stabilization of the damaged structures with the restoration of the spatial relationship of the spine are ensured. Thus, positive clinical and radiological results were achieved in 34 patients with severe thoracolumbar dislocations treated with the SSI technology in all cases that persisted throughout the observation period [26]. In a prospective study, Machino et al. reported high efficiency of simultaneous posterior screw or hook fixation and anterolateral decompression with autologous grafting in the treatment of patients with burst fractures of the thoracolumbar spine which was performed within the same anesthetic session with the patient on his/her side [27].

#### ***Simultaneous interventions the treatment of tuberculous spondylitis***

The incidence of tuberculosis varies and depends on the conditions of economic development of a certain country [28]. The spinal column is the most common extrapulmonary localization of tuberculosis infection

[29]. Tuberculous spondylitis takes the first place in the structure of the incidence of osteoarticular types of tuberculosis; it accounts for 45.2 to 82.4 % of all cases [28]. Tuberculosis of the spine was first described by Pott in 1877 as a kyphotic spinal deformity with paraplegia [30]. Starting in the 1960s, Hodgson et al. [31] proposed anterior arthrodesis with a graft to fill the defect after reconstruction of the anterior support column, which later became a classic treatment for tuberculous spondylitis. However, high incidence of unsatisfactory outcomes associated with an increased resorption of the graft such as a loss of deformity correction and instability, led to the development of the concept of internal fixation using metal structures. Treatment of active spinal tuberculosis with SSI (simultaneous anterior extirpation of a tuberculous lesion and posterior instrumental fixation with a patient being turned over within a single anesthetic session) is effective for correcting spinal deformity with restoration of the physiological sagittal balance and maintaining fixation until bone fusion has completed [32].

#### ***Rare use of simultaneous interventions***

A number of authors describe rare cases of SSI technology application in the treatment of congenital scoliosis of the spine of grades III–IV, neurofibromatosis with degenerative disease of the spine and the case of lung tumor resection with subsequent posterior instrumentation fixation of the thoracic spine [12, 33–39].

The incidence of congenital scoliosis is one to 3 cases per 1,000 newborns [34, 35], of which 15 to 38 % have been diagnosed with anomalies in the development of the spinal cord [40]. This group of diseases is the target category for the SSI. Among malformations, Chiari anomaly, diastematomyelia, lipomas and lipomenigocele, teratomas, and syringomyelia have been mentioned most frequently [33, 34, 36]. In these cases, simultaneous correction of spinal deformity and associated congenital anomalies of the spinal cord or tumor resection is performed. The use of SSI is economically advantageous, as it reduces the number of anesthesia sessions, duration of hospitalization and the rehabilitation period [37].

The use of SSIs in spinal deformities due to neurofibromatosis has been also described. In such cases, a combined operation is used: corpectomy of the affected vertebrae, bone autograft (fragment of the rib or ilium), posterior screw fixation of the affected spine [38]. The simultaneous nature of this operation performed by one surgical team consists in, first, a corpectomy and placement of a bone graft through the lateral approach, and then transpedicular screw fixation is performed from the posterior approach.

Spinal metastases are observed in three to 5 % of

oncological patients [12]. Such cases require not only combined surgical interventions, but also the joint work of surgeons of several specialties. A SSI case was described in 2013 by Stoker et al. During the operation, using the technology of video-assisted thoracoscopic surgery, the affected lung was removed along with the vertebra into which the tumor invaded. Then, a screw-based stabilizing structure was installed from the posterior approach in the area of the affected spine [39].

#### **Comparison of simultaneous surgical interventions with staged surgical treatment**

The authors found several studies which compare the SSI results with staged surgical treatment. Thus, in surgical treatment of degenerative tandem stenosis

of the cervical and lumbar spine Aydogan et al. [42], Epstein et al. [43] and Hsieh et al. [44] in a series of cases (8, 12 and 12 patients, respectively) indicate the advantages of staged surgical interventions over simultaneous ones. However, Kikuike et al. [45] and Overley et al. [10] report the best results of retrospective observation of patients after SSI at the cervical and lumbar levels.

Eskander et al. compared the indicators of intraoperative blood loss and duration of surgical intervention in SSI (21 patients) and the staged method (22 patients) [46]. It was found that the number of complications in both groups was comparable, but SSI was associated with a larger volume of blood loss.

### DISCUSSION

Due to the current lack of systematization on the use of SSI technologies in spinal surgery, there are no unified algorithms for their application. Moreover, the largest number of such operations, according to specialized literature, has been recorded in the treatment of patients with degenerative diseases of the spine. However, the results of applying the SSI technique are contradictory. In relation to other pathologies presented in the review, there is little information on the use of SSI.

At present, the significant fact is absence of a clear classification and qualitative features by which spinal surgery can be classified as a simultaneous or single-event procedure. After the analysis of the literature data, we identified several SSI types performed within the same anesthesia session: simultaneous interventions by two surgical teams from two different approaches in different anatomical areas [10], single-event sequential interventions performed by one surgical team from two different approaches in different anatomical areas [46], consecutive interventions of one surgical team from two different approaches in the same anatomical region without changing patient's position [14, 21], consecutive

interventions by one surgical team from two different approaches to one anatomical region with the change of patient's position [16, 26, 27, 32].

The study of the results of using SSI in spinal surgery showed that at the moment it is impossible to objectively compare the two proposed methods in the treatment of spinal diseases. To assess the advantages and disadvantages of each of the methods, it is necessary to increase the sample of patients, to form representative groups according to the leading nosological condition, age, comorbidity, and so on. In addition, multicenter randomized controlled trials are needed to clarify the indications for SSI in spinal neurosurgery.

**Limitations of the study** This systematic review has several drawbacks that need to be pointed at. The randomized controlled trials were not included in the systematic review, since the authors were unable to find any randomized controlled trials comparing the SSI technology with staged treatment. The majority of studies included in the systematic review were retrospective, had a small number of analyzed patients and a short-term period of postoperative observation, which significantly reduces the evidence of the results.

### CONCLUSION

Simultaneous surgical interventions with the use of high-tech tools and minimally invasive surgical techniques can simultaneously eliminate several diseases, maintain a low invasive approach, activate patients early after the operation, and reduce the number of complications. There is a need to study the effectiveness of various spinal SSIs based on such parameters as duration of surgery, time,

terms of inpatient treatment, duration of intraoperative radiation exposure and economic costs. The development of specialized criteria and a clear classification would simplify the understanding of the term "SSI", will contribute to the development of this technology in spinal neurosurgery and will help to objectively examine the results of such interventions.

**Source of funding** *The study was supported by a grant from the Innovation Assistance Fund under the UMNİK program. The number of the announced project is 48868.*

**Conflict of interests** *The authors of this article have confirmed that there is no conflict of interests to declare.*

## REFERENCES

- Sharif S., Afsar A. Learning Curve and Minimally Invasive Spine Surgery. *World Neurosurg.*, 2018, vol. 119, pp. 472-478. DOI: 10.1016/j.wneu.2018.06.094
- Hashem S., Abdelbar A., Ibrahim H., Alaa-Eldin Habib M., Abdel-Monem A., Hamdy H. Review of device and operator related complications of transpedicular screw fixation for the thoracic and lumbar regions. *Egypt J. Neurol Psychiat. Neurosurg.*, 2012, vol. 49, pp. 393-398.
- Mobbs R.J., Phan K., Malham G., Seex K., Rao P.J. Lumbar interbody fusion: techniques, indications and comparison of interbody fusion options including PLIF, TLIF, MI-TLIF, OLIF/ATP, LLIF and ALIF. *J. Spine Surg.*, 2015, vol. 1, no. 1, pp. 2-18. DOI: 10.3978/j.issn.2414-469X.2015.10.05.
- Markin S.P., Simonovich A.E., Vaikalov A.A., Krutko A.V., Kozlov D.M. Maloinvazivnaia metodika zadnego poiasnichnogo mezhtelovogo spondilodeza s ispolzovaniem endoskopicheskoi tekhniki [Minimally invasive technique of the posterior lumbar interbody spondylodesis using endoscopic technique]. *Khirurgiia Pozvonochnika*, 2007, no. 2, pp. 62-65. (in Russian)
- Imada A.O., Huynh T.R., Drazin D. Minimally invasive versus open laminectomy/discectomy, transforaminal lumbar, and posterior lumbar interbody fusions: a systematic review. *Cureus*, 2017, vol. 9, no. 7, pp. e1488. DOI: 10.7759/cureus.1488.
- Passias P.G., Ma Y., Chiu Y.L., Mazumdar M., Girardi F.P., Mementsoudis S.G. Comparative safety of simultaneous and staged anterior and posterior spinal surgery. *Spine*, 2012, vol. 37, no. 3, pp. 247-255. DOI: 10.1097/BRS.0b013e31821350d0.
- Liberati A., Altman D.G., Tetzlaff J., Mulrow C., Gøtzsche P.C., Ioannidis J.P., Clarke M., Devereaux P.J., Kleijnen J., Moher D. The PRISMA statement for reporting systematic reviews and meta-analyses of studies that evaluate health care interventions: explanation and elaboration. *J. Clin. Epidemiol.*, 2009, vol. 62, no. 10, pp. e1-e34. DOI:10.1016/j.jclinepi.2009.06.006.
- Wells G.A., Shea B., O'Connell D., Peterson J., Welch V., Losos M., Tugwell P. The Newcastle-Ottawa Scale (NOS) for assessing the quality of nonrandomized studies in meta-analyses. Available at: [http://www.ohrica.com/programs/clinical\\_epidemiology/oxfordasp](http://www.ohrica.com/programs/clinical_epidemiology/oxfordasp).
- Straus B.N. Chronic pain of spinal origin: the costs of intervention. *Spine*, 2002, vol. 27, no. 22, pp. 2614-2619.
- Overley S.C., Kim J.S., Gogel B.A., Merrill R.K., Hecht A.C. Tandem Spinal Stenosis: A Systematic Review. *JBJS Rev.*, 2017, vol. 5, no. 9, pp. e2. DOI: 10.2106/JBJS.RVW.17.00007.
- Byvaltsev V.A., Kalinin A.A., Shepelev V.V., Krutko A.V., Pestriakov Iu.Ia. Khirurgicheskaia taktika lecheniia patsientov s tandemstenozom sheinogo i poiasnichnogo otdelov pozvonochnika na osnove differentsirovannogo kliniko-instrumentalnogo algoritma [Surgical tactics of treating patients with tandem stenosis of the cervical and lumbar spine based on a differentiated clinical-instrumental algorithm]. *Travmatologia i Ortopedia Rossii*, 2018, no. 24 (1), pp. 53-64. (in Russian)
- White B.D., Stirling A.J., Paterson E., Asquith-Coe K., Melder A. Diagnosis and Management of Patients at Risk of or with Metastatic Spinal Cord Compression: Summary of NICE Guidance. *BMJ*, 2008, vol. 337, pp. a2538.
- Drazin D., Kim T.T., Johnson J.P. Simultaneous Lateral Interbody Fusion and Posterior Percutaneous Instrumentation: Early Experience and Technical Considerations. *Biomed. Res. Int.*, 2015, vol. 2015, pp. 458284. DOI: 10.1155/2015/458284.
- Jain A.K., Dhammi I.K., Jain S., Kumar J. Simultaneously anterior decompression and posterior instrumentation by extrapleural retroperitoneal approach in thoracolumbar lesions. *Indian J. Orthop.*, 2010, vol. 44, no. 4, pp. 409-416. DOI: 10.4103/0019-5413.69315.
- Kiyoshi T., Osamu T., Toshio D. Simultaneous Use of Both Bilateral Intralaminar and Pedicle Screws for C2 Stabilization. *Asian Spine J.*, 2015, vol. 9, no. 5, pp. 789-793. DOI: 10.4184/asj.2015.9.5.789.
- Cheung J.P., Luk K.D. Complications of Anterior and Posterior Cervical Spine Surgery. *Asian Spine J.*, 2016, vol. 10, no. 2, pp. 385-400. DOI: 10.4184/asj.2016.10.2.385.
- Leontev M.A. Epidemiologiia spinalnoi travmy I chastota polnogo anatomicheskogo povrezhdeniia spinnoego mozga [Epidemiology of spinal injury and frequency of complete anatomical damage of the spinal cord]. *Materialy Nauch.-Prakt. "Aktualnye problemy Reabilitatsii Invalidov", posviashchennoi Evropeiskomu i Ros. godu invalidov-2003, 60-letiiu Kemerovskoi obl., 25-letiiu Federal. Gos. Uchrezhdeniia "Novokuznetskii Nauchno-Prakt. Tsentri Mediko-Sotsialnoi Ekspertizy i Reabilitatsii Invalidov"* [Proc. Scientific-Practical Conference "Actual Problems of Rehabilitation of the Disabled Persons" devoted to European and Russian Year of Disabled-2003, 60-th anniversary of the Kemerovo Region, 25-th anniversary of Federal State Institution "Novokuznetsk Scientific-Practical Centre of Medicosocial Examination and Rehabilitation of Disabled]. *Meditsina v Kuzbasse*, 2003. Spets. Vyp., pp. 37-38. (in Russian)
- Hadley M.N., Walters B.C., Grabb P.A., Oyesiku N.M., Przybylski G.J., Resnick D.K., Ryken T.C. Isolated fractures of the axis in adults. *Neurosurgery*, 2002, vol. 50, no. 3 Suppl., pp. S125-S139. DOI: 10.1097/00006123-200203001-00021.
- Ramikh E.A. Povrezhdeniia verkhnego sheinogo otdela pozvonochnika: diagnostika, klassifikatsii, osobennosti lecheniia [Injuries of the upper cervical spine: diagnosis, classifications, features of treatment]. *Khirurgiia Pozvonochnika*, 2004, no. 3, pp. 8-19. (in Russian)
- Shinbo J., Sameda H., Ikenoue S., Takase K., Yamaguchi T., Hashimoto E., Enomoto T., Kanazuka A., Mimura M. Simultaneous anterior and posterior screw fixations confined to the axis for stabilization of a 3-part fracture of the axis (odontoid, dens, and hangman fractures): report of 2 cases. *J. Neurosurg. Spine*, 2014, vol. 20, no. 3, pp. 265-269. DOI: 10.3171/2013.12.SPINE12448.
- Koller H., Assuncao A., Kammermeier V., Holz U. Simultaneous anterior arthrodesis C2-3 and anterior odontoid screw fixation for stabilization of a 4-part fracture of the axis – a technical description. *J. Spinal Disord. Tech.*, 2006, vol. 19, no. 5, pp. 362-367.
- Byvaltsev V.A., Kalinin A.A. Analiz rezultatov reduksii kifoticheskoi deformatsii metodom minimalno-invazivnoi transpedikuliarnoi stabilizatsii u patsientov s travmaticheskimi kompressionnymi perelomami grudo-poiasnichnoi lokalizatsii [Analysis of the results of reducing kyphotic deformity by the method of minimally invasive transpedicular stabilization in patients with traumatic compression fractures of the thoracolumbar localization]. *Vestnik Khirurgii im.I.I. Grekova*, 2017, no. 176, pp. 64-71. (in Russian)
- Dhall S.S., Wadhwa R., Wang M.Y., Tien-Smith A., Mummaneni P.V. Traumatic thoracolumbar spinal injury: an algorithm for minimally invasive surgical management. *Neurosurg. Focus*, 2014, vol. 37, no. 1, pp. E9. DOI: 10.3171/2014.5.FOCUS14108.
- Langrana N.A., Harten R.D., Lin D.C., Reiter M.F., Lee C.K. Acute thoracolumbar burst fractures: a new view of loading mechanisms. *Spine*, 2002, vol. 27, no. 5, pp. 498-508.
- Xia Q., Xu B., Zhang J. The choice and evaluation of anterior, posterior or combined surgery for thoracolumbar burst fractures. *Zhonghua Gu Ke Za Zhi*, 2004.
- Xia Q., Xu B.S., Zhang J.D., Miao J., Li J.G., Zhang X.L., Zhou J. Simultaneous combined anterior and posterior surgery for severe thoracolumbar fracture dislocations. *Orthop. Surg.*, 2009, vol. 1, no. 1, pp. 28-33. DOI: 10.1111/j.1757-7861.2008.00006.x.
- Machino M., Yukawa Y., Ito K., Nakashima H., Kato F. Posterior/anterior combined surgery for thoracolumbar burst fractures – posterior instrumentation with pedicle screws and laminar hooks, anterior decompression and strut grafting. *Spinal Cord*, 2011, vol. 49, no. 4, pp. 573-579. DOI: 10.1038/sc.2010.159.
- Kulchavenia E.V., Koveshnikova E.Iu., Zhukova I.I. Kliniko-epidemiologicheskie osobennosti sovremennogo tuberkuleznogo spondillita [Clinical and epidemiological features of modern tuberculous spondylitis]. *Tuberkulez i Bolezni Legkikh*. 2013, no. 1, pp. 41-45. (in Russian)
- Garg R.K., Somvanshi D.S. Spinal tuberculosis: a review. *J. Spinal Cord Med.*, 2011, vol. 34, no. 5, pp. 440-454. DOI:10.1179/2045772311Y.0000000023.

30. Slucky A.V., Eismont F.J. Spinal infections. In: Bridwell K.H., DeWald R.L., eds. *The Textbook of Spinal Surgery*. Ed 2. Philadelphia: Lippincott-Raven, 1997, vol. 2, pp. 2141-2183.
31. Hodgson A.R., Stock F.E., Fang H.S., Ong G.B. Anterior spinal fusion. The operative approach and pathological findings in 412 patients with Pott's disease of the spine. *Br. J. Surg.*, 1960, vol. 48, pp. 172-178. DOI: 10.1002/bjs.18004820819.
32. Mukhtar A.M., Farghaly M.M., Ahmed S.H. Surgical treatment of thoracic and lumbar tuberculosis by anterior interbody fusion and posterior instrumentation. *Med. Princ. Pract.*, 2003, vol. 12, no. 2, pp. 92-96. DOI: 10.1159/000069113.
33. Belmont P.J. Jr., Kuklo T.R., Taylor K.F., Freedman B.A., Prahinski J.R., Kruse R.W. Intraspinal anomalies associated with isolated congenital hemivertebra: the role of routine magnetic resonance imaging. *J. Bone Joint Surg. Am.*, 2004, vol. 86, no. 8, pp. 1704-1710.
34. Chen B., Yuan Z., Chang M.S., Huang J.H., Li H., Yang W.Z., Luo Z.J., Tao H.R. Safety and efficacy of one-stage spinal osteotomy for severe and rigid congenital scoliosis associated with split spinal cord malformation. *Spine*, 2015, vol. 40, no. 18, pp. E1005-E1013. DOI: 10.1097/BRS.0000000000001039.
35. Gupta N., S.R., G.B., Shetty A. Vertebral and intraspinal anomalies in Indian population with congenital scoliosis: a study of 119 consecutive patients. *Asian Spine J.*, 2016, vol. 10, no. 2, pp. 276-281. DOI: 10.4184/asj.2016.10.2.276.
36. Kaplan K.M., Spivak J.M., Bendo J.A. Embryology of the spine and associated congenital abnormalities. *Spine J.*, 2005, vol. 5, no. 5, pp. 564-576.
37. Singrakhia M., Malewar N., Deshmukh S., Deshmukh S. Simultaneous Surgical Treatment of Congenital Spinal Deformity Associated with Intraspinal Anomalies. *Asian Spine J.*, 2018, vol. 12, no. 3, pp. 466-475. DOI: 10.4184/asj.2018.12.3.466.
38. Shahcheraghi G.H., Tavakoli A.R. Corpectomy and circumferential spinal fusion in dystrophic neurofibromatous curves. *J. Child. Orthop.*, 2010, vol. 4, no. 3, pp. 203-210. DOI: 10.1007/s11832-010-0253-y
39. Stoker G.E., Buchowski J.M., Kelly M.P., Meyers B.F., Patterson G.A. Video-assisted thoracoscopic surgery with posterior spinal reconstruction for the resection of upper lobe lung tumors involving the spine. *Spine J.*, 2013, vol. 13, no. 1, pp. 68-76. DOI: 10.1016/j.spinee.2012.11.026.
40. Shen J., Wang Z., Liu J., Xue X., Qiu G. Abnormalities associated with congenital scoliosis: a retrospective study of 226 Chinese surgical cases. *Spine*, 2013, vol. 38, no. 10, pp. 814-818. DOI: 10.1097/BRS.0b013e31827ed125.
41. Kepler C.K., Yu A.L., Gruskay J.A., Delasotta L.A., Radcliff K.E., Rihn J.A., Hilibrand A.S., Anderson D.G., Vaccaro A.R. Comparison of open and minimally invasive techniques for posterior lumbar instrumentation and fusion after open anterior lumbar interbody fusion. *Spine J.*, 2013, vol. 13, no. 5, pp. 489-497. DOI: 10.1016/j.spinee.2012.10.034.
42. Aydogan M., Ozturk C., Mirzanli C., Karatoprak O., Tezer M., Hamzaoglu A. Treatment approach in tandem (concurrent) cervical and lumbar spinal stenosis. *Acta Orthop. Belg.*, 2007, vol. 73, no. 2, pp. 234-237.
43. Epstein N.E., Epstein J.A., Carras R., Murthy V.S., Hyman R.A. Coexisting cervical and lumbar spinal stenosis: diagnosis and management. *Neurosurgery*, 1984, vol. 15, no. 4, pp. 489-496.
44. Hsieh C.H., Huang T.J., Hsu R.W. Tandem spinal stenosis: clinical diagnosis and surgical treatment. *Changgheng Yi Xue Za Zhi*, 1998, vol. 21, no. 4, pp. 429-435.
45. Kikuike K., Miyamoto K., Hosoe H., Shimizu K. One-staged combined cervical and lumbar decompression for patients with tandem spinal stenosis on cervical and lumbar spine: analyses of clinical outcomes with minimum 3 years follow-up. *J. Spinal Disord. Tech.*, 2009, vol. 22, no. 8, pp. 593-601. DOI: 10.1097/BSD.0b013e3181929cbd.
46. Eskander M.S., Aubin M.E., Drew J.M., Eskander J.P., Balsis S.M., Eck J., Lapinsky A.S., Connolly P.J. Is there a difference between simultaneous or staged decompressions for combined cervical and lumbar stenosis? *J. Spinal Disord. Tech.*, 2011, vol. 24, no. 6, pp. 409-413. DOI: 10.1097/BSD.0b013e318201bf94.

Received: 01.04.2019

#### Information about the authors:

1. Vadim A. Byvaltsev, M.D., Ph.D.,  
Irkutsk State Medical University, Irkutsk, Russian Federation,  
Railway Clinical Hospital on Irkutsk-Passazhirskiy station, Irkutsk, Russian Federation,  
Irkutsk Scientific Center of Surgery and Traumatology, Irkutsk, Russian Federation,  
Irkutsk State Medical Academy of Postgraduate Education, Irkutsk, Russian Federation,  
Email: byval75vadim@yandex.ru, <http://orcid.org/0000-0003-4349-7101>
2. Andrey A. Kalinin, M.D., Ph.D.  
Irkutsk State Medical University, Irkutsk, Russian Federation,  
Railway Clinical Hospital on Irkutsk-Passazhirskiy station, Irkutsk, Russian Federation,  
Email: andrei\_doc\_v@mail.ru, <https://orcid.org/0000-0002-6059-4344>
3. Sergey O. Ryabykh, M.D., Ph.D.,  
Ilizarov National Medical Research Centre for Traumatology and Orthopedics, Kurgan, Russian Federation,  
Email: rso\_@mail.ru, <https://orcid.org/0000-0002-8293-0521>
4. Alexander V. Burtsev, M.D., Ph.D.,  
Ilizarov National Medical Research Centre for Traumatology and Orthopedics, Kurgan, Russian Federation,  
Email: bav31rus@mail.ru, <https://orcid.org/0000-0001-8968-6528>
5. Valerij V. Shepelev, M.D., Ph.D.,  
Irkutsk State Medical University, Irkutsk, Russian Federation,  
Email: shepelev.dok@mail.ru, <https://orcid.org/0000-0001-5135-8115>
6. Sergey V. Ochkal, M.D.,  
Irkutsk State Medical University, Irkutsk, Russian Federation,  
Email: ostin.vl@mail.ru, <https://orcid.org/0000-0002-9969-8845>
7. Roman A. Polkin, M.D.,  
Irkutsk State Medical University, Irkutsk, Russian Federation,  
Email: roman.polkin@gmail.com, <https://orcid.org/0000-0003-4490-3212>
8. Mikhail Yu. Biryuchkov, M.D., Ph.D., Professor,  
West Kazakhstan Marat Ospanov Medical University, Aktobe, Kazakhstan,  
Email: biryuchkov@mail.ru, <https://orcid.org/0000-0003-4821-2654>